

IgG/IgA pemphigus in a 41-year-old Filipino female: case report

Bryan Edgar K Guevara,¹ Armand T Merton,¹ Lalaine R Visitacion^{1,2}

¹Department of Dermatology, Southern Philippines Medical Center, JP Laurel Ave, Davao City, Philippines

²Davao Medical School Foundation, Medical School Drive, Bajada, Davao City, Philippines

Correspondence

Bryan Edgar K Guevara
bry0529@yahoo.com

Received

31 May 2015

Accepted

29 June 2015

Cite as

Guevara BEK, Merton AT, Visitacion LR. IgG/IgA pemphigus in a 41-year-old Filipino female: case report. *SPMC J Health Care Serv.* 2015;1(1):38-41.

Copyright

© 2015 BEK Guevara, et al.

ABSTRACT

IgG/IgA pemphigus is a newly described variant of pemphigus, a group of autoimmune intraepidermal blistering diseases. Unlike lesions in other variants that are characterized by the presence of only either IgG or IgA autoantibodies, IgG/IgA pemphigus lesions have deposits of both intercellular IgA and IgG autoantibodies in the epidermis. We report the case of a 41-year-old female with a one-year history of multiple pruritic papules, plaques and vesicles, evolving into erosions and crusts on the chest, trunk, axilla, gluteal area, and extensor surfaces of extremities. Diagnosis of IgG/IgA pemphigus was confirmed through skin biopsy and the identification of both granular intercellular IgG and IgA antibodies within the epidermis through direct immunofluorescence. In this patient, we found out that treatment with dapsone alone was successful, with complete resolution of lesions after two weeks and no recurrence within four months.

Keywords. vesiculobullous skin disease, direct immunofluorescence, dapsone monotherapy

INTRODUCTION

Pemphigus is a potentially fatal autoimmune mucocutaneous group of diseases that produce antibodies against cell surface antigens, like desmoglein (Dsg), on keratinocytes. This results in the separation of the keratinocytes and manifests as blisters.¹ This blistering

disease is classically divided into two major types: pemphigus vulgaris and pemphigus foliaceus, which are associated with IgG autoantibodies to Dsg3 and Dsg1, respectively.² Non-classical forms of pemphigus exist, such as paraneoplastic pemphigus, IgA pemphigus, and IgG/IgA pemphigus.²⁻³ Both IgG and IgA antibodies that target intercellular components of the epidermis are present in IgG/IgA pemphigus.⁴ We report the clinical features, diagnostic approaches and therapeutic management of a patient with IgG/IgA pemphigus.

CLINICAL FEATURES

A 41-year old Filipino female came to our clinic due to multiple papules and vesicles (Figure 1). The condition started a year prior to consultation as multiple pruritic papules and vesicles, which progressed to patches and plaques with erosions on the chest, trunk, axilla, gluteal area, and extensor surfaces of the extremities. There were no fever, pain, or body malaise. No medications were taken or applied on the skin before

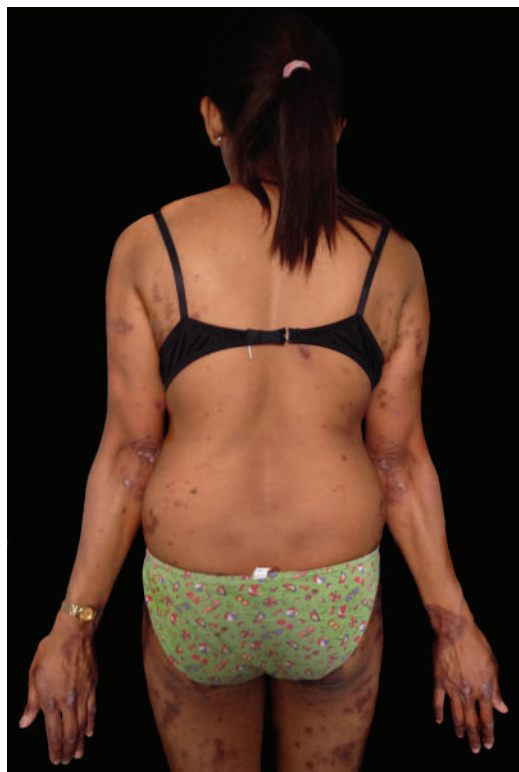

Figure 1 Multiple erythematous papules and plaques, and a few intact vesicles on the back, extensor surfaces of the extremities and gluteal areas.

IN ESSENCE

IgG/IgA pemphigus is a newly described and distinct form of vesiculobullous disease.

Direct immunofluorescence is needed to confirm the diagnosis of IgG/IgA pemphigus.

Dapsone monotherapy can be an adequate therapeutic intervention for patients with IgG/IgA pemphigus.



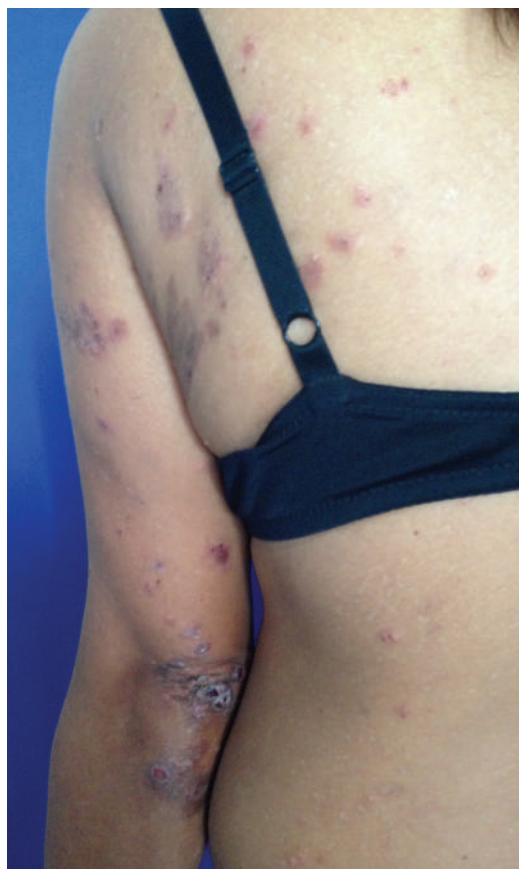

Figure 2 Closer view of erythematous papules and plaques, with erosions and crusts.

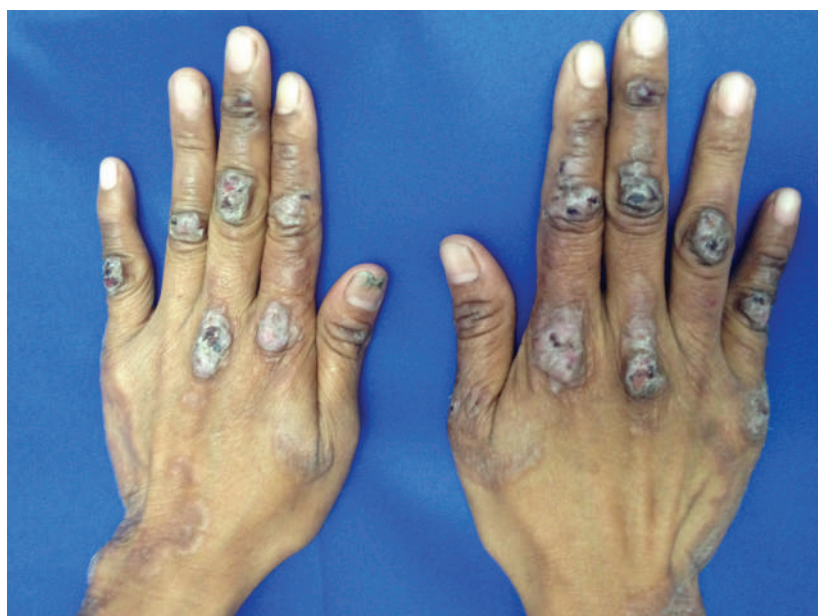

Figure 3 Hyperpigmented and lichenified plaques with erosions on the dorsum of the hands.

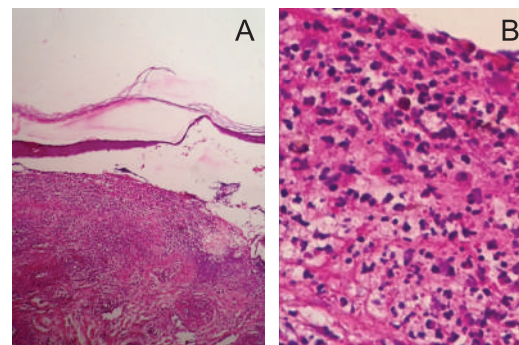


Figure 4 Photomicrograph of the cutaneous biopsy showing acantholytic epidermis, formation of subcorneal and subepidermal blister, and dermal edema containing neutrophils and eosinophils (hematoxylin-eosin stain, A: x10, B: x40).

onset of the lesions. The patient consulted several dermatologists, but she could not recall their working diagnoses for her condition. She was prescribed with oral antihistamines and topical steroids, which did not improve the lesions. Medical, social, and family histories were unremarkable.

Dermatologic examination revealed multiple erythematous papules and a few intact or tense vesicles with erosions and crusts on the chest, trunk, axilla, extensor surfaces of extremities, and gluteal area (Figures 1, 2, 3). The oral and genital mucosae were free of lesions. The shearing of the epidermis upon lateral pressure of unblistered skin, or Nikolsky's sign, was negative. The rest of the physical examination was unremarkable.

Differential diagnoses for vesiculobullous skin lesions, such as those that we found in the patient, include dermatitis herpetiformis, pemphigus vulgaris and IgA pemphigus. These diagnoses are clinically difficult to distinguish from each other, since they manifest similarly with multiple vesicles. The use of immunofluorescence methods that can detect antibodies in the intercellular spaces of the epidermis and/or circulating antibodies in the serum can differentiate these vesiculobullous diseases.

DIAGNOSTICS APPROACHES

We requested for hematologic tests, serum chemistry, and glucose-6-phosphate dehydrogenase (G6PD) level, which were all within normal limits. Skin tissue biopsy of an intact vesicle located on the upper back revealed subcorneal and subepidermal split, with a few acantholytic cells, and neutrophilic and eosinophilic inflammatory infiltrates (Figures 4A, 4B). The biopsy result was consistent with any of the vesi-

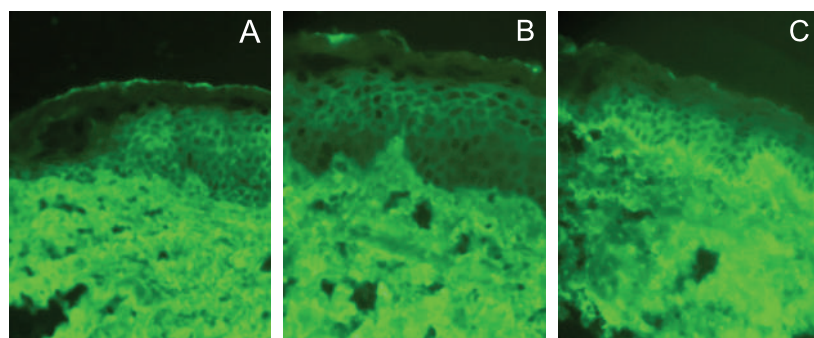


Figure 5 Direct immunofluorescence of the perilesional skin showing granular intercellular deposits of IgG (A), C3 (B), IgA (C) (x40).

culobullous diseases that we considered, hence we requested for direct immunofluorescence (DIF) to detect intercellular deposits of IgG or IgA. The DIF result revealed that the specimen was positive for granular intercellular deposits of C3, and both IgG and IgA. This finding is consistent with the overlap pemphigus variant, IgG/IgA pemphigus (Figure 5A, 5B, 5C). Detection of serum autoantibodies to Dsg1, Dsg3 and desmocollin 1 could not be done because these tests were not available in the local setting. To rule out any concomitant malignancies at baseline, we ordered chest radiography, and abdominal and pelvic ultrasonography, which were all within normal limits.

THERAPEUTIC APPROACHES

Dapsone 50 mg daily for six weeks proved effective in immediately controlling the lesions. Mupirocin 2% ointment twice a day for one week was also applied to the eroded areas of the skin in order to prevent infection.

OUTCOMES

After two weeks of dapsone therapy, the lesions completely resolved, leaving only residual hypopigmented and hyperpigmented macules and patches on the previously affected areas. Dapsone was then continued for one more month. There was no recurrence or appearance of new lesions within the six-week dapsone therapy.

DISCUSSION

IgG/IgA pemphigus has been described as an overlap of IgA pemphigus with either pemphigus foliaceus or pemphigus vulgaris.⁵ Only 21 patients with this atypical form of pemphigus have been reported in the literature, and the true incidence of the

disease is unknown.⁶ The age of onset varies from 11 to 81 years, and the disease is more common in women.^{4,7} To the best of our knowledge, this is the first reported case in the Philippines.

Histologically, IgG/IgA pemphigus is a neutrophilic acantholytic bullous disease, which contains both intercellular deposits of IgA and IgG antibodies within the epidermis.^{7,8} Its associated target antigens include Dsg1 (similar to pemphigus vulgaris), Dsg3 (similar to pemphigus foliaceus),⁷⁻⁹ and desmocollin 1 (similar to IgA pemphigus).⁷⁻¹⁰ This heterogeneity of target antigens makes the clinical and histologic features of IgG/IgA pemphigus complex and varied.

The clinical presentation of IgG/IgA pemphigus is often variable and share many clinical features with other pemphigus variants. Lesions can include pruritic papules, plaques, vesicles, and pustules on the trunk and extremities, with rare involvement of the oral and genital mucosae.^{7-9,11,12} As with patients in previous reports, our patient presented with multiple pruritic papules, plaques and vesicles on the trunk and extensor surfaces of the extremities. When we contemplated starting the patient on dapsone therapy, we requested for G6PD testing due to the risk of hemolysis among patients with G6PD deficiency on sulfone drugs.¹³ IgG/IgA pemphigus may be associated with malignancies, such as lung, ovarian, and gallbladder carcinoma, hence there is a need to repeat the cancer screening regularly in the future.³

As an overlap pemphigus variant, IgG/IgA pemphigus demonstrates varied histologic features such as those seen upon histologic examination of our patient's lesions. DIF, which revealed both IgG and IgA intercellular deposits in the epidermis, defined the diagnosis of IgG/IgA pemphigus.

Unlike the pemphigus variants associated with IgG (pemphigus vulgaris and pemphigus foliaceus), those that are associated with IgA (IgA pemphigus and IgG/IgA pemphigus) are not often controlled by steroids alone.¹⁴ IgA deposits act as ligands for neutrophil attachment.¹³ The accumulation of neutrophils that produce proteolytic enzymes are responsible for epidermal acantholysis.¹³ Hence, dapsone, a sulfone drug that inhibits neutrophil chemotaxis and lysosomal activity, is an appropriate therapy for this condition.¹⁵ Systemic or topical steroids, and retinoids are alternatives

if this sulfone drug cannot be tolerated due to hemolytic anemia.¹⁶ Treatments with dapsone monotherapy, prednisolone monotherapy, and combinations of dapsone, retinoids, minocycline, and steroids have been reported to be successful in treating IgG/IgA pemphigus.⁶ In our patient, successful treatment with dapsone monotherapy for six weeks was achieved. We monitored the patient every week for four weeks, then monthly thereafter up to 4 months, in order to watch out for possible recurrence of lesions, but we did not note any. Hematologic tests, such as erythrocyte sedimentation rate and complete blood count, which we requested every follow-up to detect hemolysis, all turned out to be within normal limits.

There has been no published local and international studies regarding the prognosis and recurrence rate of IgG/IgA pemphigus. However, several reports have concluded that dapsone monotherapy has been an effective therapy for induction of remission.⁴

The long-standing symptoms of the patient prompted for a definite diagnosis of her condition. We achieved this by doing DIF, which revealed the overlap variant, IgG/IgA pemphigus. We successfully treated the patient with dapsone monotherapy. Regular monitoring of the patient will ensure treatment adherence and early detection of malignancies that are closely associated with this condition.

Acknowledgments

The authors would like to acknowledge the invaluable help and support of Dr Maricarr Pamela Lacuesta (Department of Dermatology, Southern Philippines Medical Center), Dr Jasmin Jamora (Department of Dermatology, St Luke's Medical Center), and Dr Johannes F Dayrit and Dr Ayees G Mendoza (Department of Dermatology, Research Institute for Tropical Medicine).

Patient consent

Obtained

Reporting guideline used

CARE Checklist (<http://www.care-statement.org/downloads/CAREchecklist-English.pdf>)

Article source

Submitted

Peer review

External

Competing interests

None declared

Access and license

This is an Open Access article licensed under the Creative Commons

Attribution-NonCommercial 4.0 International License, which allows others to share and adapt the work, provided that derivative works bear appropriate citation to this original work and are not used for commercial purposes. To view a copy of this license, visit <http://creativecommons.org/licenses/by-nc/4.0/>

REFERENCES

1. Bystryń JC, Rudolph JL. Pemphigus. *Lancet*. 2005;366(9479):61-73.
2. Robinson ND, Hashimoto T, Amagai M, Chan LS. The new pemphigus variants. *J Am Acad Dermatol*. 1999;40(5 Pt 1):649-71.
3. Porro AM, Caetano LV, Maehara LS, Enokihara MM. Non-classical forms of pemphigus: pemphigus herpetiformis, IgA pemphigus, paraneoplastic pemphigus and IgG/IgA pemphigus. *An Bras Dermatol*. 2014;89(1):96-106.
4. Maruyama H, Kawachi Y, Fujisawa Y, Itoh S, Furuta J, Ishii Y, et al. IgA/IgG pemphigus positive for anti-desmoglein 1 autoantibody. *Eur J Dermatol*. 2007;17(1):94-5.
5. Lane N, Parekh P. IgG/IgA pemphigus. *Am J Dermatopathol*. 2014;36(12):1002-4.
6. Watkins C, West C, Kosari P, Ali S, Sangüeza OP, Huang W. IgG/IgA pemphigus: report of a rare variant of atypical pemphigus and a review of the literature. *J Dermatolog Clin Res*. 2014; 2(1): 1011.
7. Santiago-et-Sánchez-Mateos D, Juárez Martín A, González De Arriba A, Delgado Jimenez Y, Fraga J, Hashimoto T et al. IgG/IgA pemphigus with IgA and IgG antidesmoglein 1 antibodies detected by enzyme-linked immunosorbent assay: presentation of two cases. *J Eur Acad Dermatol Venereol*. 2011;25(1):110-2.
8. Nakajima K, Hashimoto T, Nakajima H, Yokogawa M, Ikeda M, Kodama H. IgG/IgA pemphigus with dyskeratotic acantholysis and intraepidermal neutrophilic microabscesses. *J Dermatol*. 2007;34(11):757-60.
9. Oiso N, Yamashita C, Yoshioka K, Amagai M, Komai A, Nagata Y, et al. IgG/IgA pemphigus with IgG and IgA antidesmoglein 1 antibodies detected by enzyme-linked immunosorbent assay. *Br J Dermatol*. 2002;147(5):1012-7.
10. Chorzelski TP, Hashimoto T, Nishikawa T, Ebihara T, Dmochowski M, Ismail M, et al. Unusual acantholytic bullous dermatosis associated with neoplasia and IgG and IgA antibodies against bovine desmogleins I and II. *J Am Acad Dermatol*. 1994;31(2 Pt 2):351-5.
11. Kowalewski C, Hashimoto T, Amagai M, Jablonska S, Mackiewicz W, Wozniak K. IgA/IgG pemphigus: a new atypical subset of pemphigus?. *Acta Derm Venereol*. 2006;86(4):357-8.
12. Zarea I, Kerkeni N, Sellami M, Chelly I, Zitouna M, Makni S, et al. IgG/IgA pemphigus with IgG and IgA antidesmoglein 3 antibodies and IgA antidesmoglein 1 antibodies detected by enzyme-linked immunosorbent assay: a case report and review of the literature. *Int J Dermatol*. 2010;49(3):298-302.
13. Press P, Committee PF. BNF for Children 2011-2012. Pharmaceutical Pr; 2011.
14. Hendrix JD, Mangum KL, Zone JJ, Gammon WR. Cutaneous IgA deposits in bullous diseases function as ligands to mediate adherence of activated neutrophils. *J Invest Dermatol*. 1990;94(5):667-72.
15. Thuong-nguyen V, Kadunce DP, Hendrix JD, Gammon WR, Zone JJ. Inhibition of neutrophil adherence to antibody by dapsone: a possible therapeutic mechanism of dapsone in the treatment of IgA dermatoses. *J Invest Dermatol*. 1993;100(4):349-55.
16. Yasuda H, Kobayashi H, Hashimoto T, Itoh K, Yamane M, Nakamura J. Subcorneal pustular dermatosis type of IgA pemphigus: demonstration of autoantibodies to desmoglein-1 and clinical review. *Br J Dermatol*. 2000;143(1):144-8.